

Effect of Probiotics on Cutaneous Wound Healing

Dr. Mitra Heydari Nasrabad
Farima Zahedi

INTRODUCTION



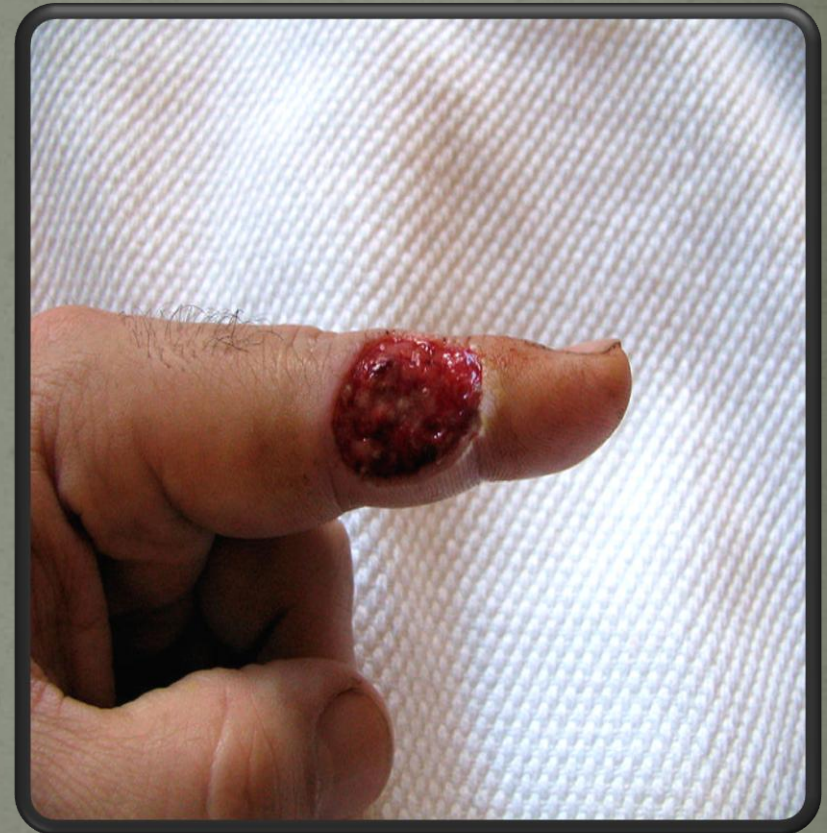PREVIOUS STUDIES

- Heydari Nasrabadi, M., Tajabadi Ebrahimi, M., Dehghan Banadaki, Sh., Torabi Kajousangi, M., Zahedi, F. (2011). Study of cutaneous wound healing in rats treated with *Lactobacillus plantarum* on days 1, 3, 7, 14 and 21. African Journal of Pharmacy and Pharmacology. 5(21): 2395-2401.
- Heydari Nasrabadi, M., Tajabadi Ebrahimi, M., Aboutalebi, H., Zahedi, F. (2011). The Healing Effect of *Lactobacillus plantarum* Isolated from Iranian Traditional Cheese on Gastric Ulcer in Rats. African Journal of pharmacy and pharmacology. 5(12): 1446-14551.
- Zahedi, F., Heydari Nasrabadi, M., Tajabadi Ebrahimi, M., Shabani, M., Aboutalebi, H. (2011). The effect of *Lactobacillus brevis* isolated from Iranian traditional cheese on cutaneous wound healing in rats. Journal of Cell and Animal Biology. 5(12): 265-270.
- Zahedi, F., Heydari Nasrabadi, M., Tajabadi Ebrahimi, M., Aboutalebi, H. (2011). Comparison of the effects of *Lactobacillus brevis* and *Lactobacillus plantarum* on cutaneous wound healing in rats. African Journal of Microbiology Research. 5(24): 4226-4233.

- .
- Koren L. et al. The Effect of Lactobacillus Bacteria Supplement on Sepsis and Its Complications in Patients with Acute Burns. *Burn* 2007;33(5):594-598

WOUND HEALING

- ❖ a **wound** is a type of injury in which skin is torn, cut or punctured (an open wound), or where blunt force trauma causes a contusion (a closed wound). In pathology, it specifically refers to a sharp injury which damages the dermis of the skin.
- ❖ Different chemical agents have been used for wound healing but each agent has negative side effects. Appropriate treatment and care is essential to accelerate the healing process. A therapeutic agent selected for the treatment of wounds should ideally improve one or more phases of healing.

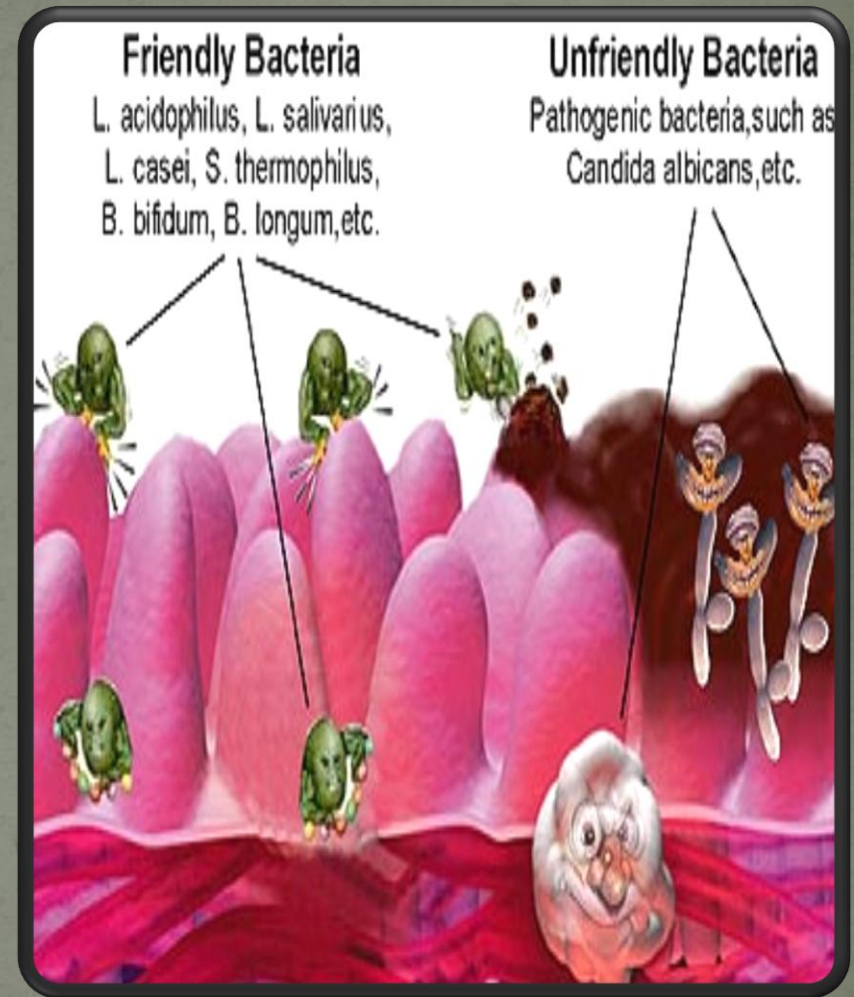


PROBIOTIC BACTERIA

❖ Probiotics and its exopolysaccharide, were both tested for antimicrobial and healing activities in chronic ulcers but though, they have many strains and species the only study on the use of probiotics on cutaneous wound healing was done by Rodrigues et al. in 2004 (Rodrigues et al., 2004).




- ❖ These bacteria have been known as beneficial factors that have many effects on human health like reduction of serum cholesterol, stimulation of immune system and prevention or treatment of human infections.



EXOPOLYSACCHARIDE (EPS)

- Probiotic bacteria produce exopolysaccharides (EPS) that can be connected to a cell's surface or that can discharge into the environment. EPS have many roles like immunostimulatory, anti tumor activity. Also, phosphate groups in EPS play an important role in activating macrophages and lymphocytes.



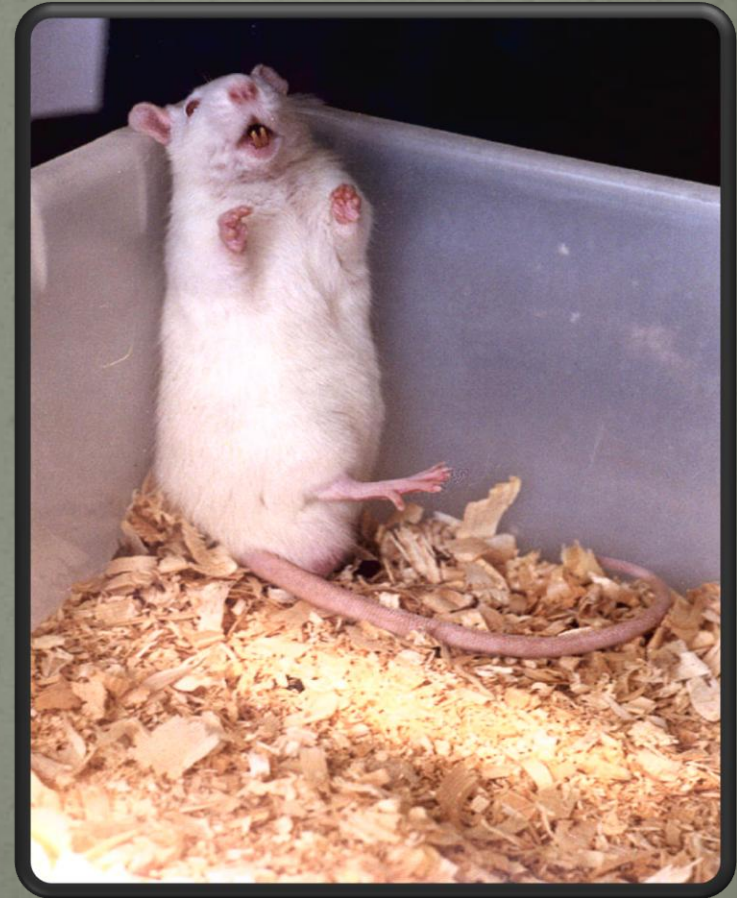
EPS around E. Sibiricum

MATERIALS & METHODS



ANIMAL HOUSING AND HANDLING

- ❖ Male Wistar rats weighting 250–280 g were housed under controlled conditions of light, room temperature and humidity.

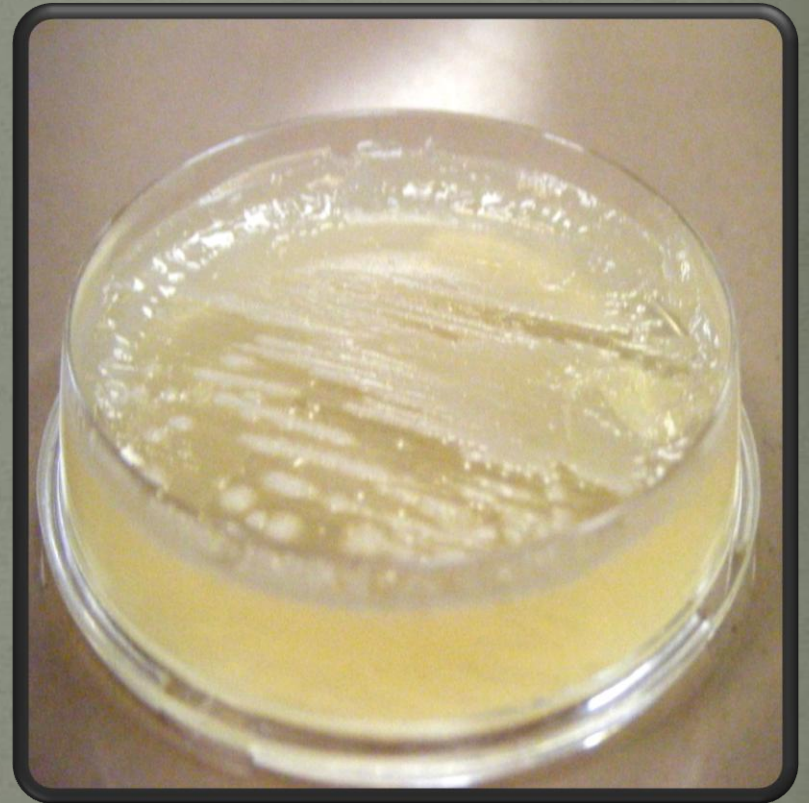

The animals were separated into five groups ($n = 7$) which contain negative control, control and three experimental groups for the days 1, 3, 7, 14 and 21.

- Negative control group : 35 mice were kept as negative controls, where the wounds were left untreated.
- Control group : A second group of 35 mice were used as control, where the wound was treated with the eucerin alone.
- Experimental 1 group : In the third set of 35 mice as experimental 1 groups, the wound was treated with the eucerin contain live *Lactobacillus casei*.
- Experimental 2 group : In the fourth set of 35 mice as experimental 2 groups, the wound was treated with the eucerin contain dead *Lactobacillus casei*.
- Experimental 3 group : In the fifth set of 35 mice as experimental 3 groups, the wound was treated with the eucerin contain *exopolysaccharide*.

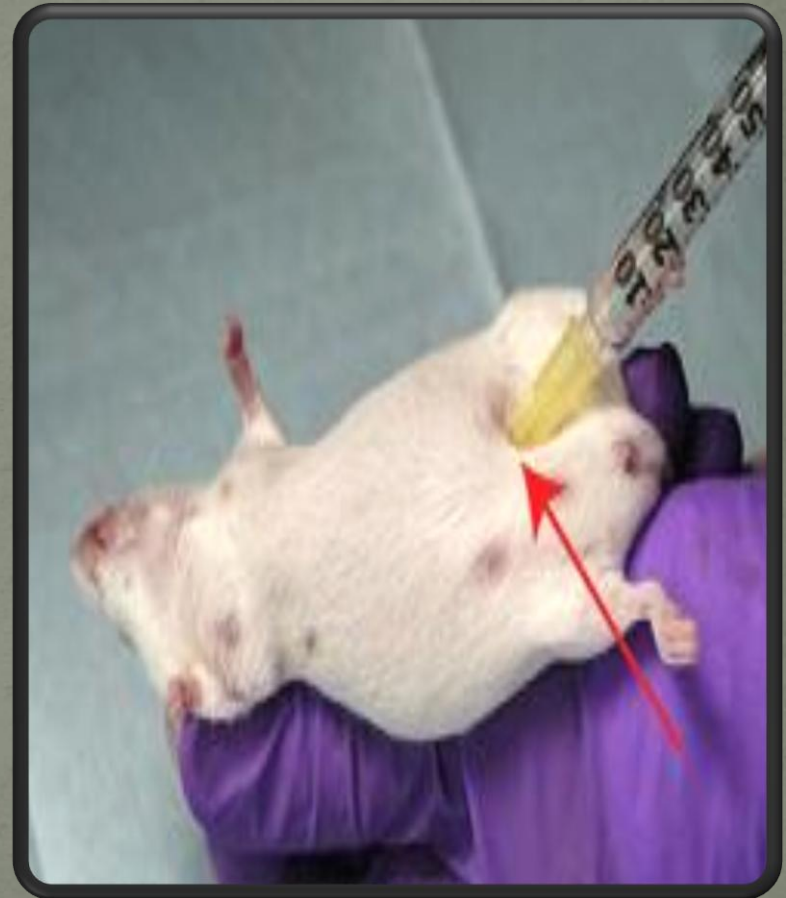OINTMENT PREPARATION

- *Lactobacilli* MRS agar, for 48 h at 37 °C
- by sterilized spoon, bacteria on the surface of culture were collected.
- In order to prepare ointment for experimental 1 and 2 groups, 1 ml bacteria that collected every day after 48-hour culture were added to 4 ml eucerin for 5 mice per as a preservative and mix thoroughly until a uniform income.
- Powder from 20 mm of the culture medium was mixed with 80 mm of eucerin.



WOUND INDUCTION

- The animals anesthetized by a mixture of ketamine and xylazine (i.p.; 15 and 20 mg/kg, respectively)
- IP injection for faster absorption of injection material

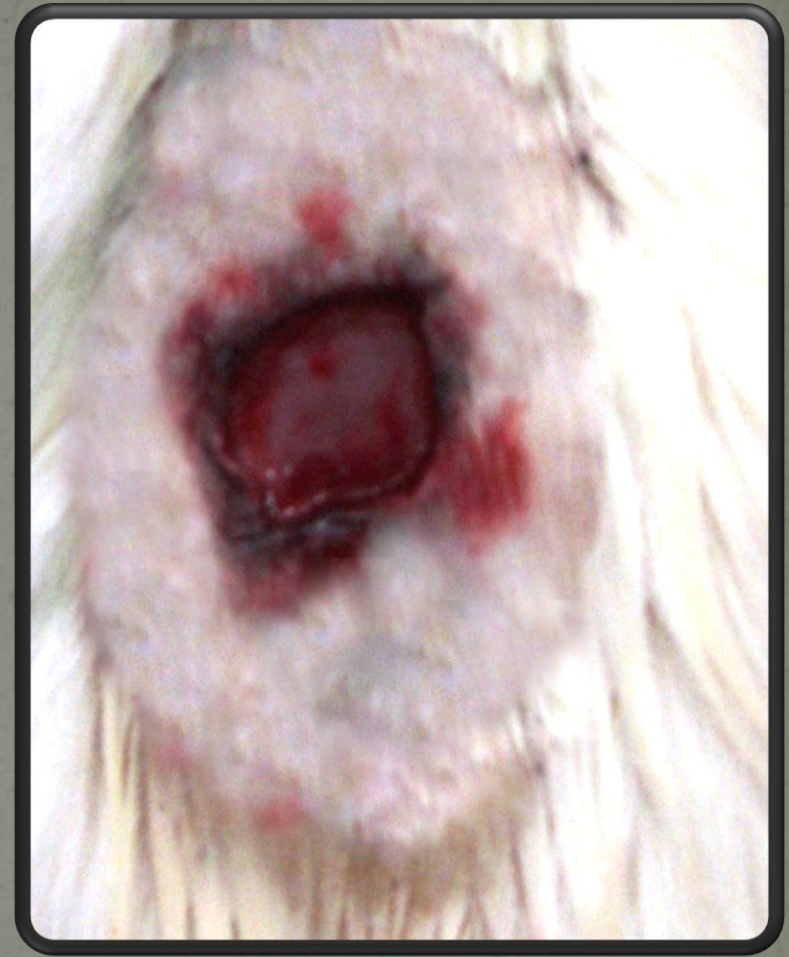

- shaving the dorsal hair
- Ethanol 60%
- One open excision full-thickness wound approximately 1.5×1.5 cm long and 6 mm deep wounds were created in the back of each mice using shablon.



skin wound

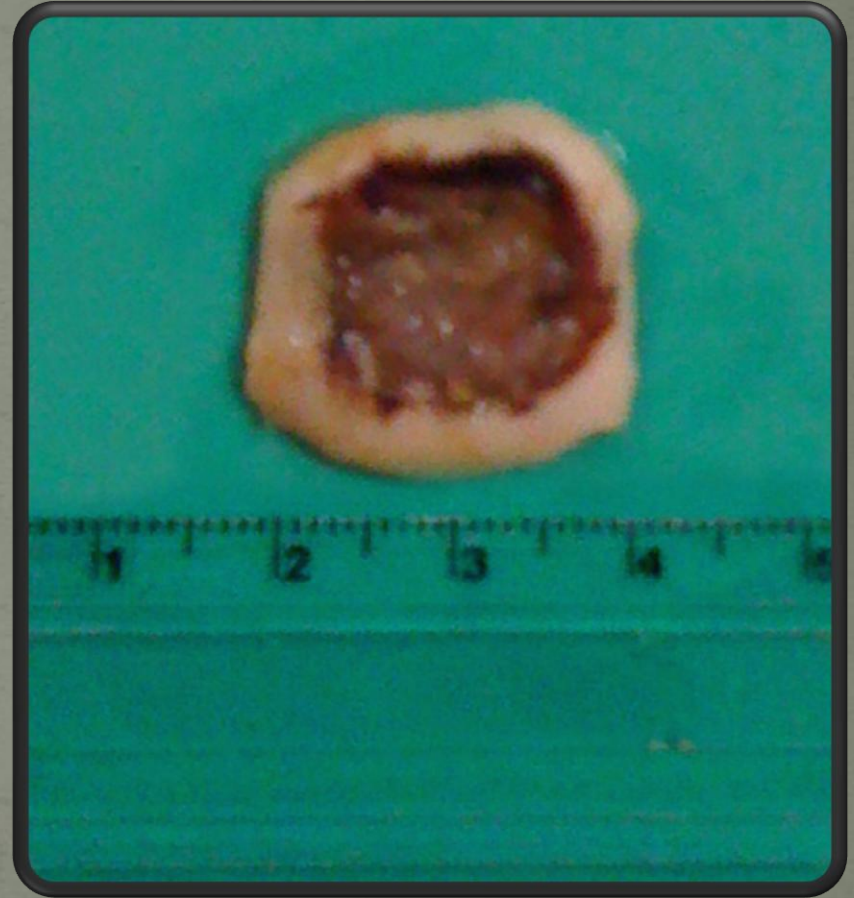
- Full-thickness wound
- Digital photographs of wounds were taken at days 1, 3, 7, 14 and 21 and the maximum length and width of each wound was measured with calipers in tertian.



Created wound on skin

HISTOLOGICAL STUDIES

- The mice were killed at 1, 3, 7, 14, 21 day after wounding. Paraffin embedded sections were prepared from skin samples including the wound and the surrounding skin were harvested using surgical blade.
- Cut perpendicular to the skin surface and included the whole thickness of the skin. Serial sections were stained with H&E



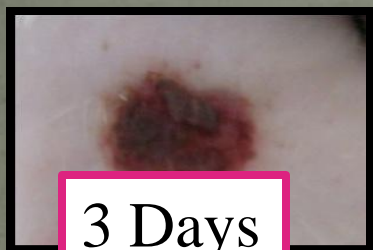RESULTS & DISCUSSION



❖ The percent of wound healing and inflammation in experimental groups as compared to control and negative control groups were significant ($p \leq 0.05$). The rate of wound healing in experimental group 1 compared with the experimental groups treated with dead bacteria and exopolysaccharide showed a significant increase ($p \leq 0.05$). The current study showed a significant reduction in inflammation and a significant acceleration in wound healing on the rats treated by live form of *Lactobacillus casei* as compared to other groups. Further studies are required for detail mechanism of *Lactobacillus* during wound healing.

Experimental

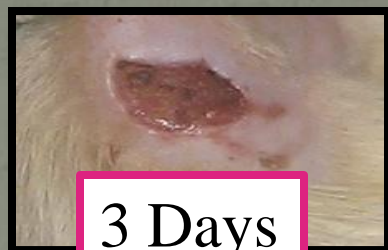1



3 Days

Experimental

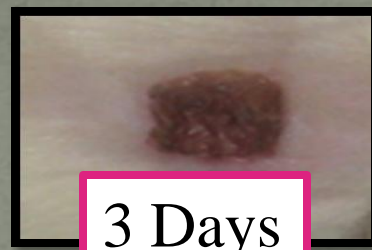2



3 Days

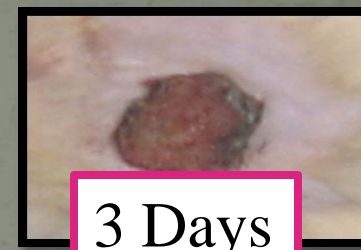Experimental

3

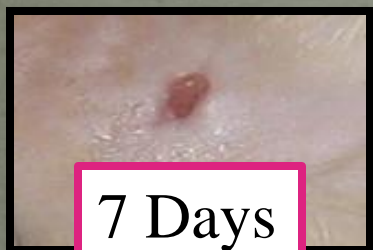

3 Days

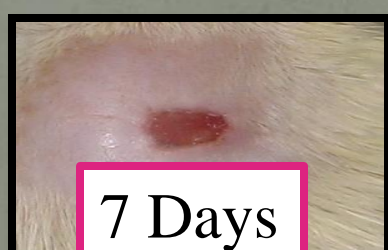Control



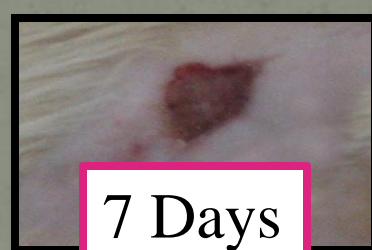3 Days



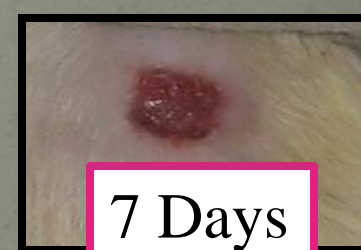7 Days



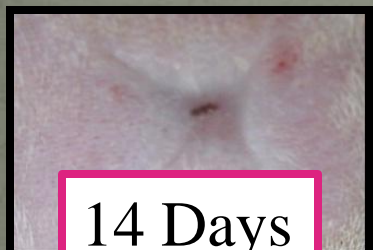7 Days



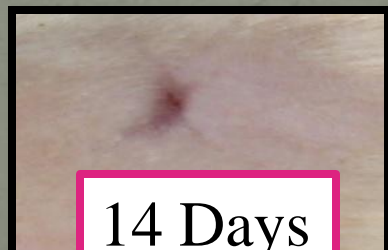7 Days



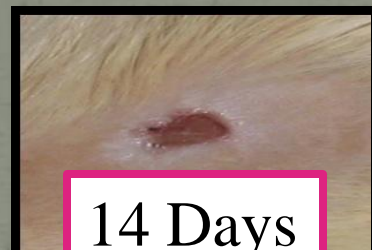7 Days



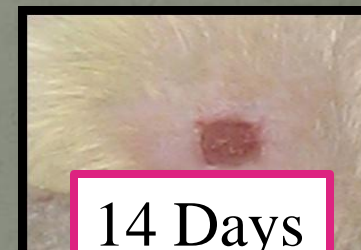14 Days




14 Days



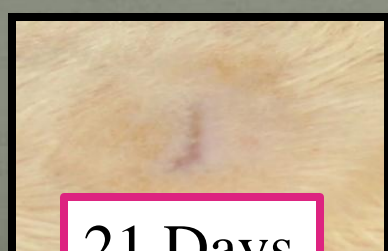14 Days



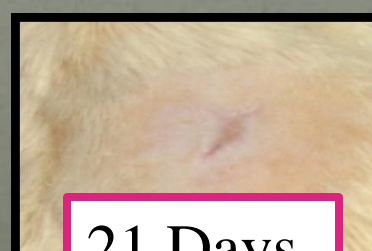14 Days



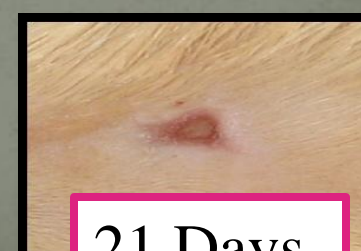21 Days



21 Days

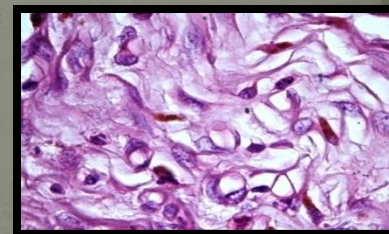
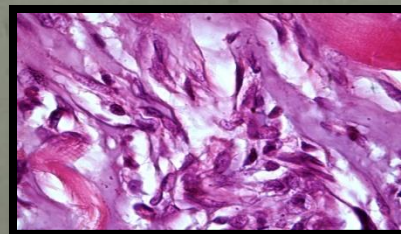
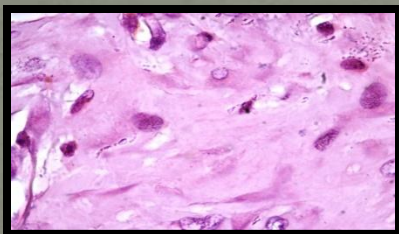
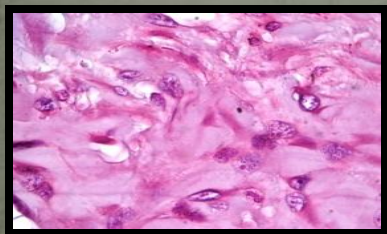
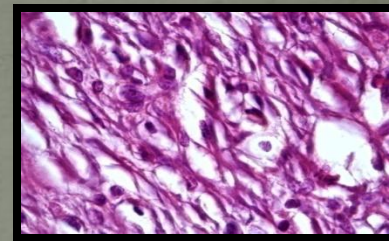
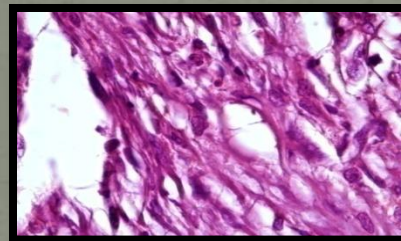
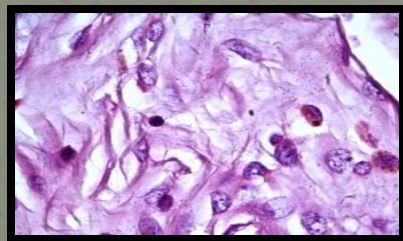
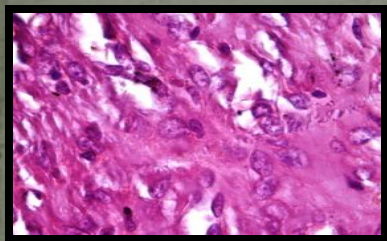
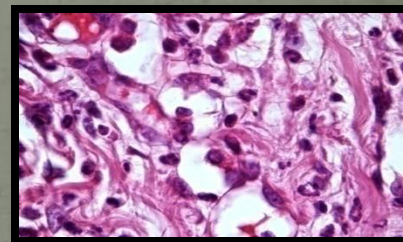
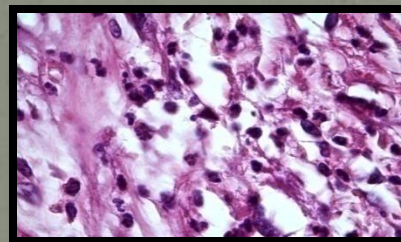
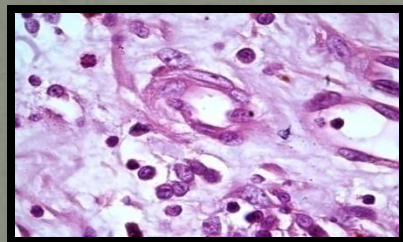
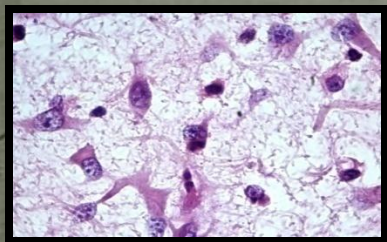


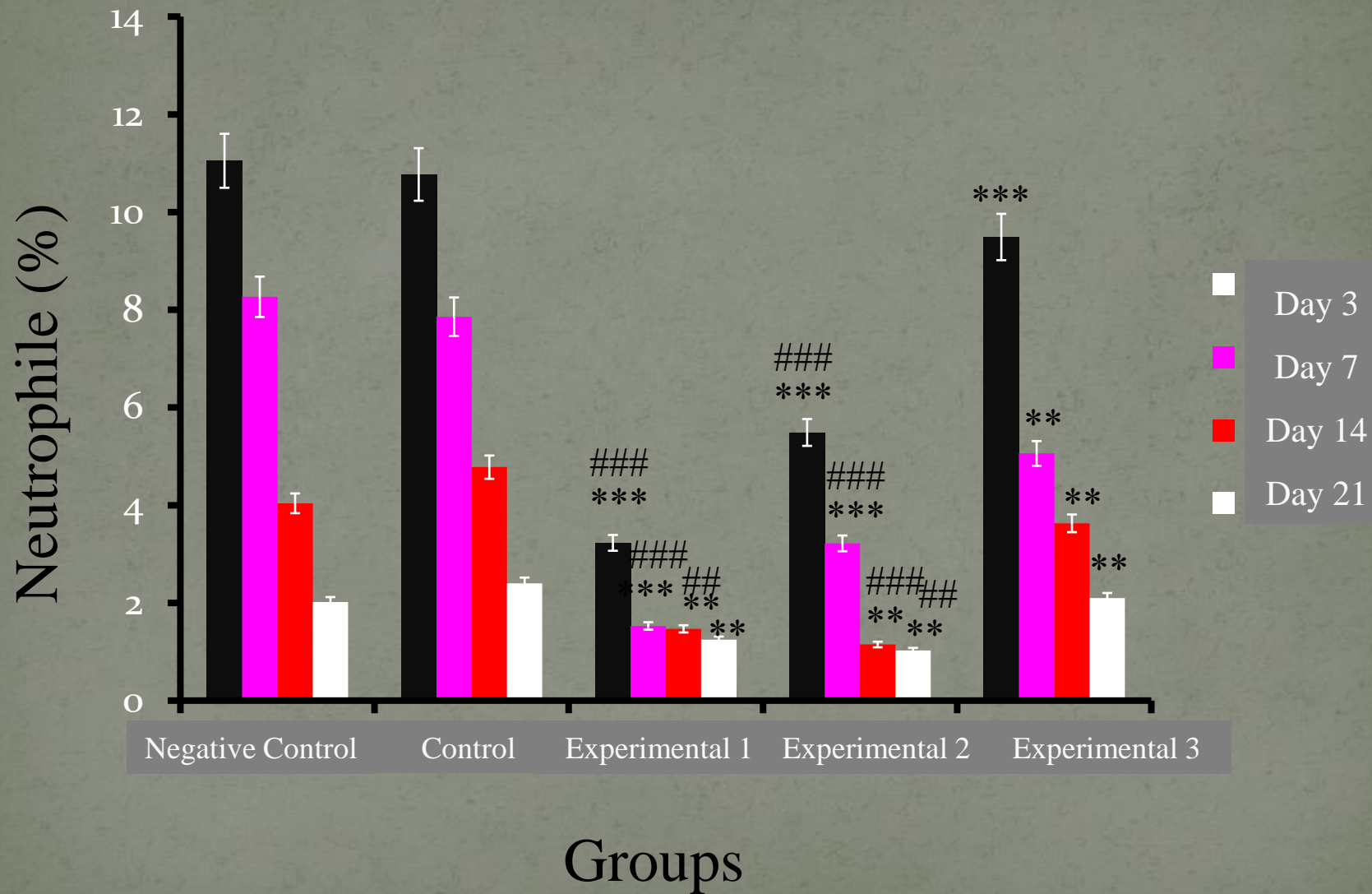
21 Days

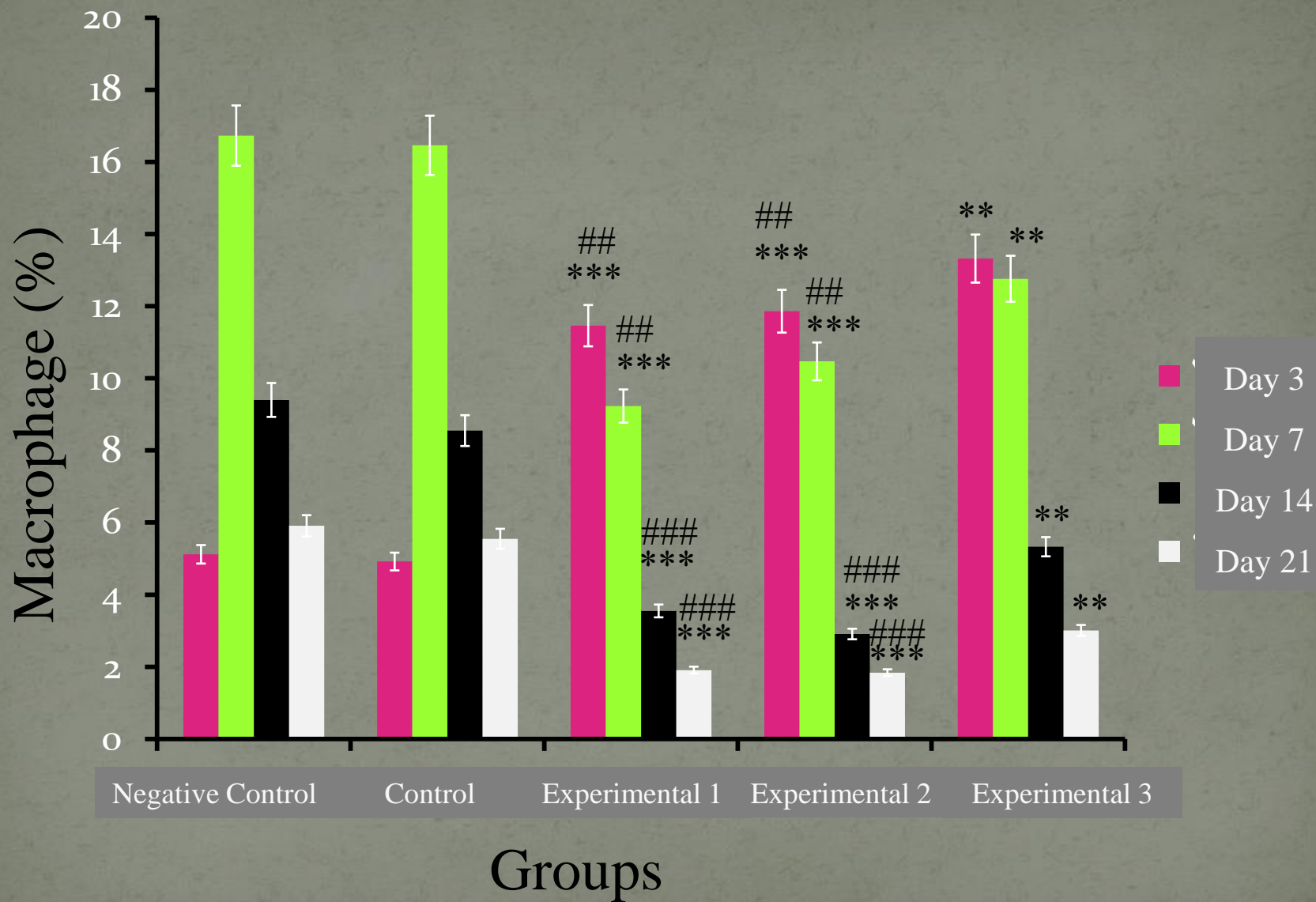


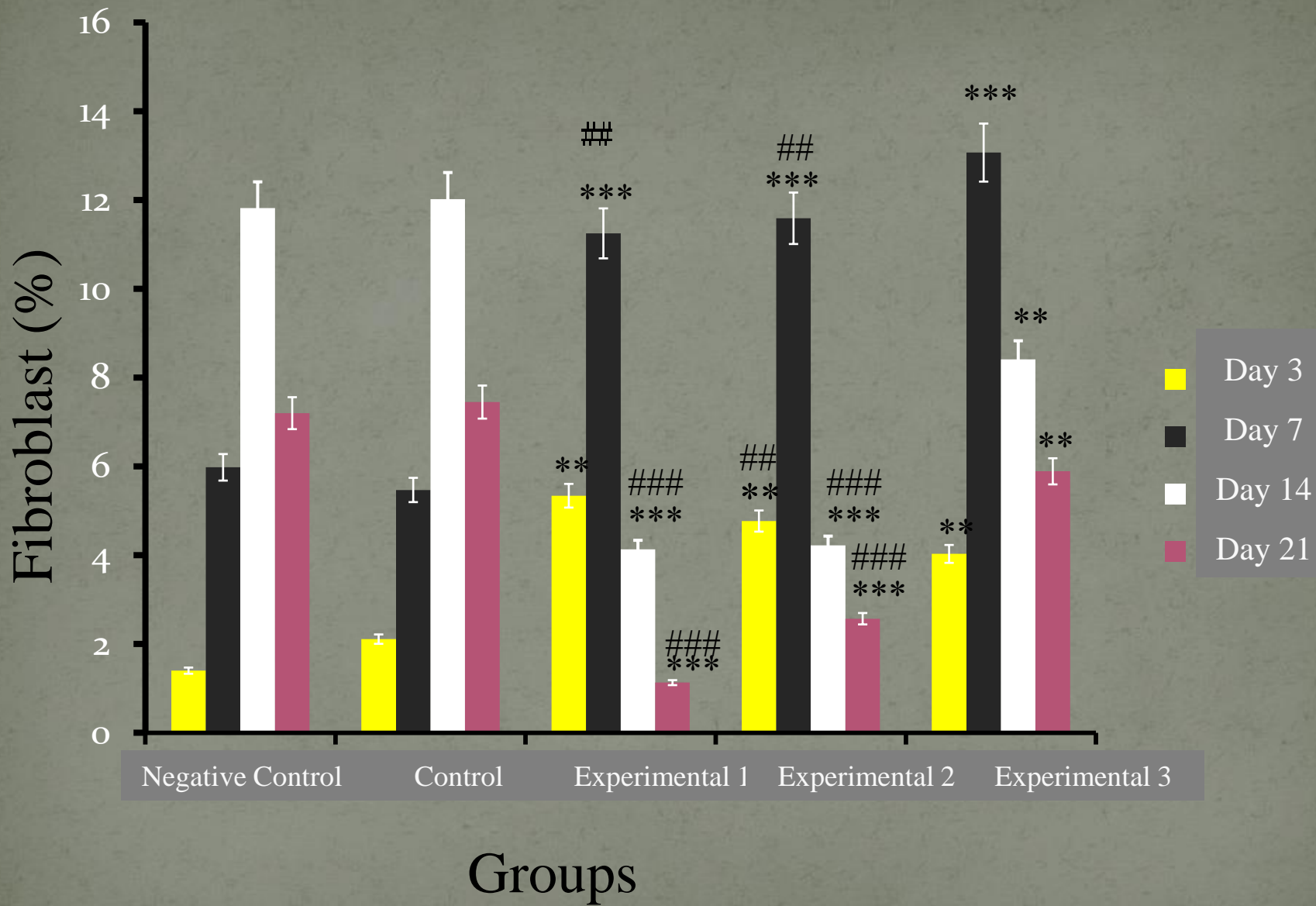
21 Days

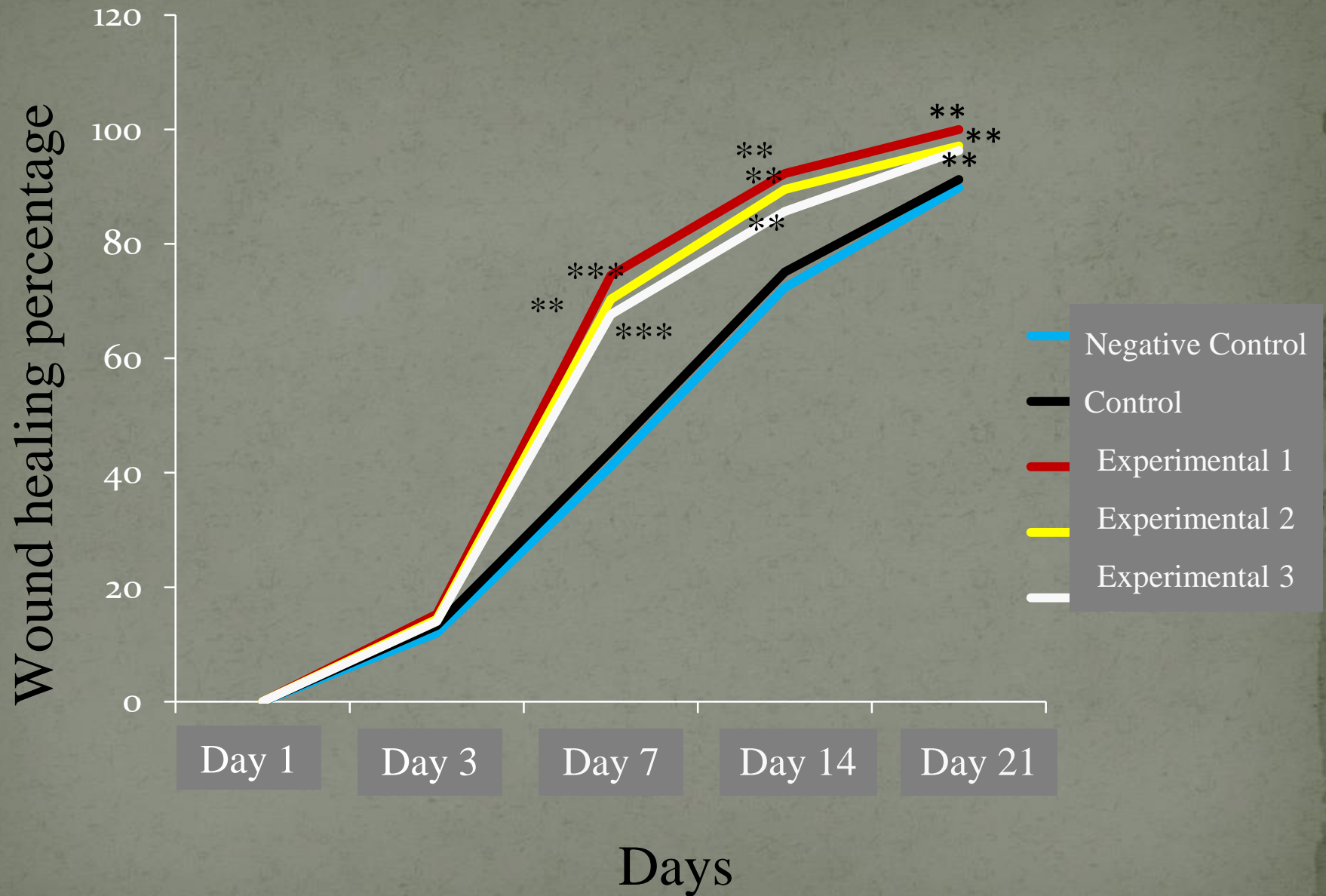
Experimental Experimental Experimental Control











*Thank you for your
attention.*